



Pediatric Rhegmatogenous Retinal Detachment Surgical Outcomes: A Systematic Review and Meta-Analysis

Fawaz M Salman^{1*}, Ahmad Alshammari², Abdullah K Ahmad M¹, Faisal Alhamdan², Aseel Al Kandari² and Alaa AlAli²

¹Mohammad Abdulrahman Albahar Eye Centre, Ibn Sina Hospital, Ministry of Health, Kuwait Institute for Medical Specializations, Kuwait

²Mohammad Abdulrahman Albahar Eye Centre, Ibn Sina Hospital, Ministry of Health, Kuwait Board of Ophthalmology, Kuwait Institute for Medical Specializations, Kuwait

Citation: Fawaz M Salman, Ahmad Alshammari, Abdullah K Ahmad M, Faisal Alhamdan, Aseel Al Kandari, et al. (2026) Pediatric Rhegmatogenous Retinal Detachment Surgical Outcomes: A Systematic Review and Meta-Analysis. J of Opt Res Therapy 2(1), 1-10. WMJ-JORT -108

Abstract

Aim: To compare the outcomes of different surgical approaches in cases of pediatric rhegmatogenous retinal detachment.

Method: A systematic review and meta-analysis were performed, and an electronic search identified all studies comparing the surgical outcomes of the different surgical approaches in cases of pediatric rhegmatogenous retinal detachment. The outcome was anatomical success from single surgery.

Results: Our systematic review and meta-analysis included 8 studies with 909 operated pediatric rhegmatogenous retinal detachment eyes with one of three procedures, pars plana vitrectomy (PPV), combined pars plana vitrectomy and scleral buckle (PPV & SB) and scleral buckle alone (SB). The pooled single surgery anatomical success rates of PPV, combined PPV & SB and SB are 63%, 66% and 81% respectively.

When considering studies that directly compared two interventions, five studies directly compared PPV with combined PPV & SB with no statistically significant difference between the two interventions with a slight advantage to combined PPV & SB. Three studies directly compared SB with PPV, and the results showed that scleral buckle has higher odds of achieving anatomical success from a single surgery. While two studies directly compared SB with combined PPV & SB and showed no significant difference in achieving anatomical success.

Conclusion: Scleral buckle is considered the most successful of the three procedures in achieving single surgery anatomical success. Combined PPV and SB can be considered in more advanced cases of rhegmatogenous retinal detachment with lower success rate. PPV is the least successful of the three interventions. Further details are required within the literature to establish an evidence-based algorithm in cases of pediatric rhegmatogenous retinal detachments to increase future success rates.

***Corresponding author:** Fawaz M Salman, Mohammad Abdulrahman Albahar Eye Centre, Ibn Sina Hospital, Ministry of Health, Kuwait Institute for Medical Specializations, Kuwait.

Submitted: 01.01.2026

Accepted: 08.01.2026

Published: 19.01.2026

Keywords : Retinal Detachment, Paediatric Rhegmatogenous Retinal Detachment, Scleral Buckle, Pars Plana Vitrectomy

Introduction

Pediatric retinal detachment is a rare condition in which management can be very challenging for vitreo-retinal surgeons. The annual incidence is 0.38-0.69 per 100,000 [1]. Etiologies of pediatric retinal detachment include trauma, high myopia, vascular causes such as ROP, FEVR, Norrie syndrome, congenital/developmental ocular disorders such as coloboma and optic pit, ocular tumours, uveitis, prior ocular surgery, systemic conditions such as Stickler syndrome, Marfan syndrome and atopic dermatitis [2,3]. Presenting symptoms and signs include decreased vision, strabismus, and leukocoria [4]. Pediatric retinal detachment has been associated with poor prognosis due to late presentation, presence of proliferative vitreoretinopathy, macula-off status, and amblyopia [4-6].

Surgical options include anterior (trans-limbal) or posterior (trans-pars plicata/pars plana) vitrectomy, scleral buckle, combined vitrectomy and scleral buckle, endoscopic vitrectomy and pneumatic retinopexy [7-9]. Unique considerations are taken for pediatric patients undergoing vitreoretinal surgery such as surgical landmarks which differ from adult eyes and thus sclerotomy distance from the limbus should be adjusted according to age [7,10].

Due to the scarcity of data on surgical outcomes of pediatric rhegmatogenous retinal detachment cases, there are no clear guidelines or algorithms in choosing the type of surgery. In the fast-evolving realm of ophthalmological interventions, periodic reviews are imperative to gauge the efficacy and outcomes of various surgical techniques. This systematic review and meta-analysis aim to compare the outcomes of different surgical approaches to provide evidence on the efficacy, advantages, and outcomes.

Eligibility Criteria

Studies were considered eligible for inclusion based on patients aged 18 years and younger who were diagnosed with a rhegmatogenous retinal detachment and had surgical intervention as well as documented post-operative outcomes published over the past 10 years.

Study Selection

The Cochrane Library, PubMed, EMBASE, and Clinical Key were the databases searched. Study selection followed a two-stage process. Initially, titles and abstracts were screened independently by two reviewers (AAS, FS) to identify potentially relevant studies. Full-text articles were then assessed for eligibility against the predetermined criteria.

Data Collection

Data extraction was conducted independently by two reviewers using a piloted data extraction form. The form was tested on a small number of included studies and refined accordingly. In our systematic review and meta-analysis, we managed to include 8 studies that were either a case series describing the outcome of one surgical intervention or retrospectively comparing two or more surgical interventions. The three main surgeries performed were pars plana vitrectomy, scleral buckle, or combined pars plana vitrectomy and scleral buckle. All studies involved cases of rhegmatogenous retinal detachments only.

Methods

Outcomes

A meta-analysis of proportions was performed to explore the outcomes of three surgical techniques to correct pediatric rhegmatogenous retinal detachment. Outcomes included the anatomic success from a single surgery in the three groups. In addition, a meta-analysis of odds ratio (OR) was performed for studies that

directly compared the three techniques.

Data Synthesis

A meta-analysis of proportions using the random-effects model was used to pool the estimates (%) of anatomical success. Without appropriate data transformation, the accompanying meta-analyses experience threats to statistical conclusion validity, such as the confidence limits falling outside of the established zero-to-one range and variance instability. Generalized linear mixed models (GLMM) using the logit link was used. At the study level, GLMMs do not require any data transformations; instead, they directly model event counts with binomial likelihoods and employ a special link function to transfer latent true proportions to a linear scale.

For comparing anatomical success and change in visual acuity between groups, the odds ratio (OR) was calculated for each study and a meta-analysis of OR was performed. The unadjusted OR were calculated using the provided counts and total numbers within each group. We selected the odds ratio as the preferred measure of effect size for categorical variables because it remains unaffected by variations in the baseline probability of the control group, which can differ among studies.

Meta-Analysis

Statistical analysis was performed using R software version 3.6.3 (R Foundation for Statistical Computing, Vienna, Austria). The random-effects model (using the maximum likelihood estimator for tau) was used to pool the effect sizes from the included studies. The underlying hypothesis for adopting the random-effects model is that heterogeneity or observed variance of effect is a sum of sampling error and variation in true-effect sizes stemming from inter-population variability. The generic inverse variance method was used to weigh each trial's per-protocol population. Forest plots were used to visualize the results. P values < 0.05 were considered statistically significant.

Prediction Interval

The prediction interval was used to assess the treatment effect that may be predicted in future analyses, considering the different settings across different studies. It captures the variability in the true treatment

effect across different settings. With substantial heterogeneity, prediction intervals will be broader than confidence intervals and might be considered a more conservative technique to integrate uncertainty in the analysis.

Sensitivity Analysis

Sensitivity analysis was performed using the leave-one-out method to assess the effect of the different studies on the estimate and heterogeneity. Sensitivity analysis was performed to assess whether the pooled estimate and between-study heterogeneity were significantly affected by the exclusion of certain studies. In addition, the forest plots were checked for possible outliers. The reasons for such behaviour were explored and the analysis was repeated after excluding outliers.

Publication Bias and Heterogeneity between Studies
Funnel plots were used to assess publication bias. Egger's test was used to test the asymmetry of funnel plots. The trim-and-fill method was also used to detect and adjust for publication bias. The I² statistic was used to explore the percentage of heterogeneity attributed to variation in true-effect sizes secondary to inter-population variation. Estimates from subgroups within the same study were pooled using a fixed-effects model and used in the meta-analysis. The 95% confidence interval (CI) and Z-statistic were calculated and used for hypothesis testing. Heterogeneity between studies was quantified using the I² statistic (I² < 25%: low heterogeneity; 25% - 50%: moderate heterogeneity; 50% - 75%: high heterogeneity; I² > 75%: substantial heterogeneity). In the case of high heterogeneity, the cause was investigated, the outlier was removed, and a new result was presented.

Risk of Bias Assessment

The methodological quality of the included observational studies was assessed using the Newcastle–Ottawa Scale (NOS) for comparative retrospective cohorts and the Joanna Briggs Institute (JBI) critical appraisal checklist for case series.

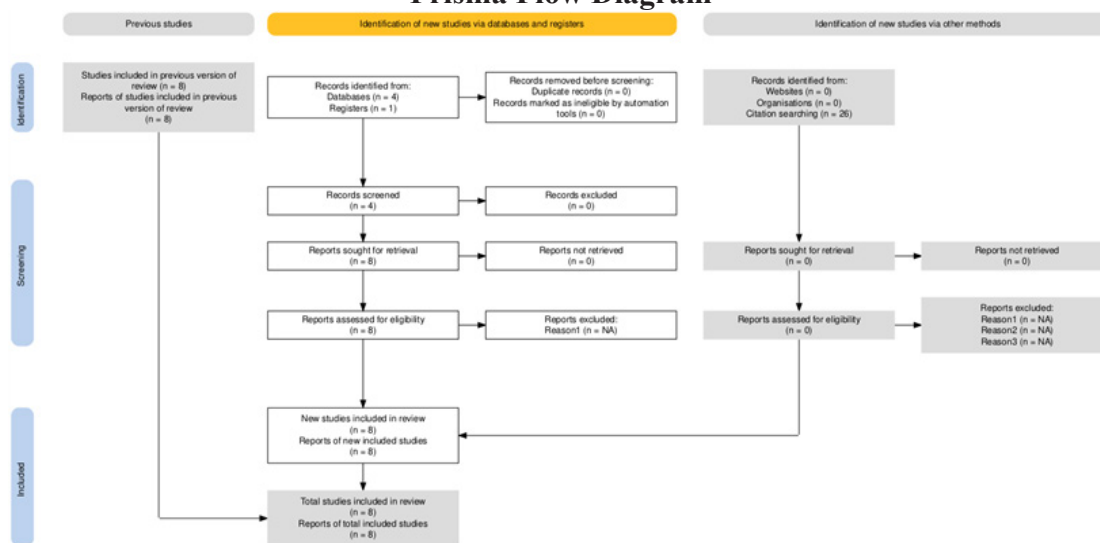
Each study was independently evaluated by two reviewers for selection, comparability, and outcome domains (NOS) or for clarity of inclusion, follow-up, and outcome reporting (JBI). (see the underlying table 1).

Discrepancies were resolved through discussion and consensus. Studies were classified as low, moderate, or high risk of bias based on total scores.

Table

STUDY	DESIGN	ASSESSMENT TOOL	SELECTION (0-4)	COMPARABILITY (0-2)	OUTCOME (0-3)	TOTAL	OVERALL RISK	MAIN SOURCES OF BIAS
AL-ZAAIDI 2013	Retrospective comparative (PPV vs PPV+SB)	NOS	3	1	2	6/9	Moderate	Limited comparability, retrospective design
ERRERA 2015	Case series (SB only)	JB	-	-	-	8/10 Yes	Low	Minimal; good case definition and follow-up
SEN 2018	Case series (PPV)	JB	-	-	-	7/10 Yes	Moderate	Incomplete follow-up, small sample size
SMITH 2019	Comparative (PPV vs PPV+SB vs SB)	NOS	4	2	3	9/9	Low	None significant
GHORABA 2020	Comparative (PPV vs PPV+SB)	NOS	3	1	2	6/9	Moderate	Non-randomized, limited confounder control
AL TAISAN 2021	Comparative (PPV vs PPV+SB)	NOS	4	2	3	9/9	Low	None significant
ATIK 2022	Case series (PPV only)	JB	-	-	-	6/10 Yes	Moderate	Small sample, incomplete outcome reporting
SPARKS 2023	Comparative (PPV vs PPV+SB vs SB)	NOS	2	1	1	4/9	High	Incomplete follow-up, selection bias

Prisma Flow Diagram



Results

Overall, methodological quality among the eight included studies was moderate to good. Three studies demonstrated a low risk of bias, four had moderate risk, and one showed high risk mainly due to incomplete follow-up data and lack of comparative controls.

Common limitations included retrospective design, variable follow-up duration, and absence of randomization. No study showed evidence of selective outcome reporting or serious methodological flaws that would invalidate its findings.

In summary, 3 studies were rated low risk, 4 were moderate, and 1 was high risk. Most limitations stemmed from the retrospective nature of the included studies and incomplete follow-up reporting.

Anatomical success

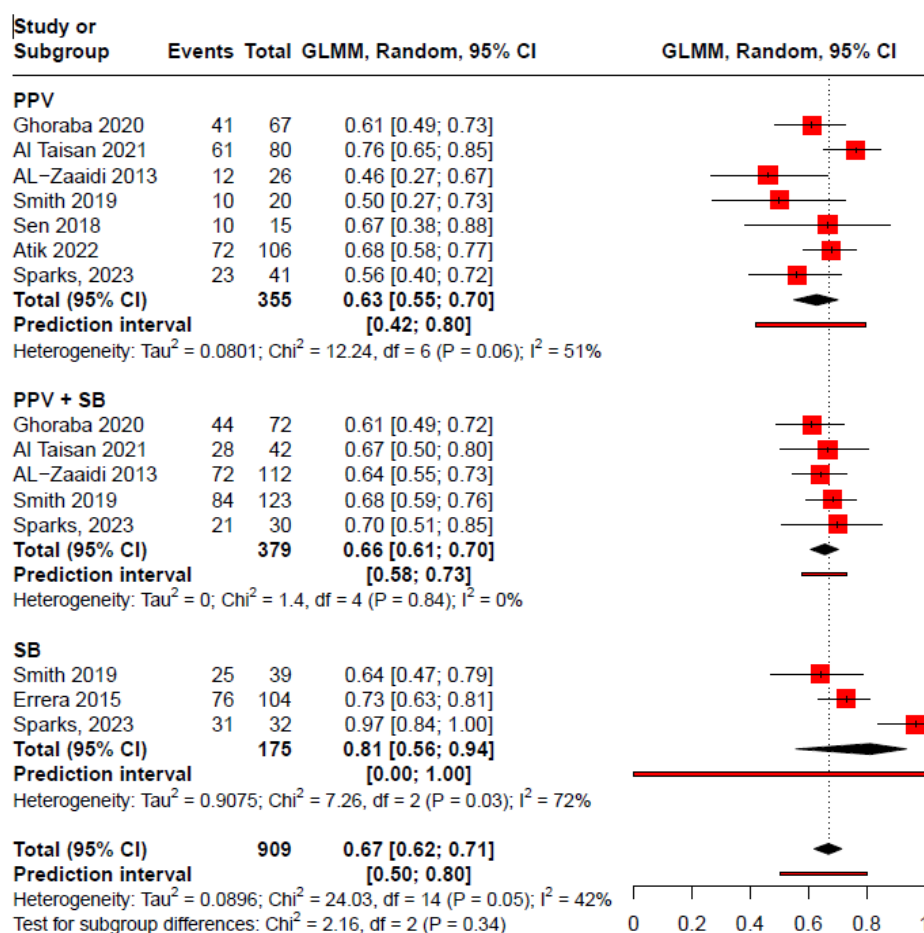


Figure 1: Forest Plot of Anatomical Success Rates in Pediatric Rhegmatogenous Retinal Detachment Surgery

Forest plot showing pooled single-surgery anatomical success rates of pars plana vitrectomy (PPV), combined pars plana vitrectomy and scleral buckle (PPV + SB), and scleral buckle (SB) in pediatric rhegmatogenous retinal detachment.

Pooled estimates were calculated using a Generalized Linear Mixed Model (GLMM) with a logit link under a random-effects framework, which directly models event counts with binomial likelihoods to provide more accurate confidence intervals for proportions and account for between-study variability.

Horizontal lines represent 95% confidence intervals; diamond shapes indicate pooled estimates.

Analysis shows that for PPV only the pooled effect size for anatomical success was 0.63 (95% CI 55%, 70%). The heterogeneity within this subgroup was 51% which was moderate. In the combined PPV & SB Subgroup, the pooled effect size was 66% (95% CI 61%, 70%). Heterogeneity was 0%, indicating consistent results across the included studies. In the SB Subgroup, the pooled effect size was 81% (95% CI 56%, 94%). The test for subgroup differences was not statistically significant (P = 0.34).

Comparison between Groups

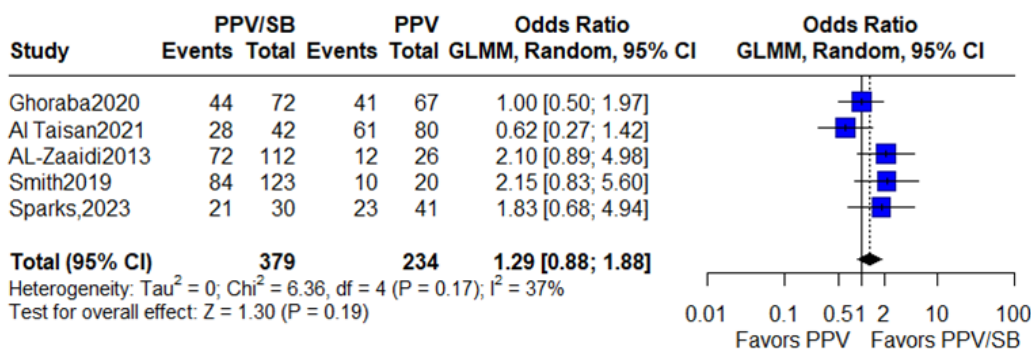


Figure 2: Comparison of Pooled Estimates for Anatomical Success between PPV only and Combined PPV & SB Groups in Pediatric Rhegmatogenous Retinal Detachment

In total, the five studies comprised 379 patients in the PPV & SB group and 234 patients in the PPV group. The pooled estimate from the random-effects model yields an odds ratio of 1.29 (95% CI 0.88, 1.88, $P = 0.19$). The heterogeneity among the studies was moderate ($I^2 = 37\%$). The pooled estimate suggests that the combined surgical approach of PPV & SB is not significantly better statistically than PPV alone although the results suggest that the combined approach was associated with 36% higher odds of success than PPV. However, they were not statistically significant at the 0.05 level.

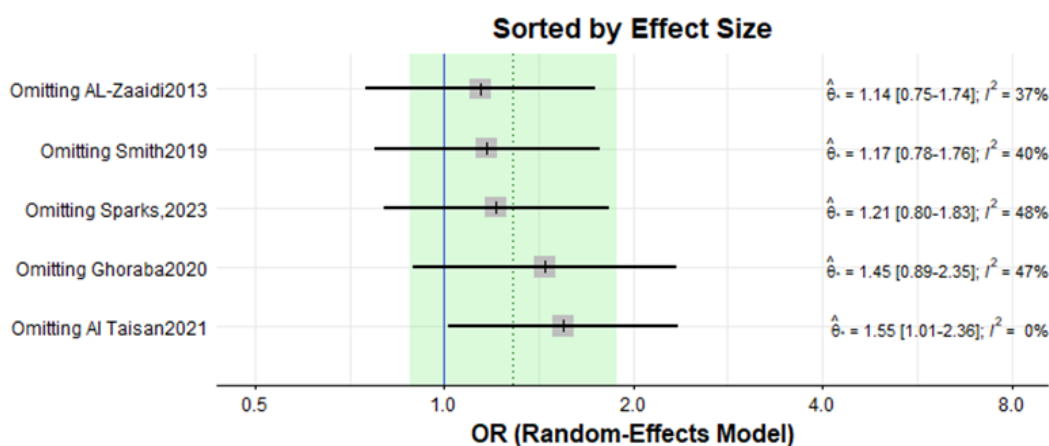


Figure 3: Sensitivity Analysis Results

Omitting each study in turn results in odds ratios (ORs) that range from 1.14 to 1.55. All the recalculated ORs were above 1, which suggests that the finding—that combined PPV & SB has a higher odd of anatomical success compared to PPV only—is robust to the removal of any single study. However, the results were statistically significant only after omitting the study by Taisan 2021. The heterogeneity (I^2) varied from 0% to 48%, with the lowest heterogeneity observed when the Al Taisan2021 study is omitted. Interestingly, when this study was removed, the OR was highest (OR = 1.55, 95% CI 1.01 – 2.36) indicating a stronger and more precise estimate.

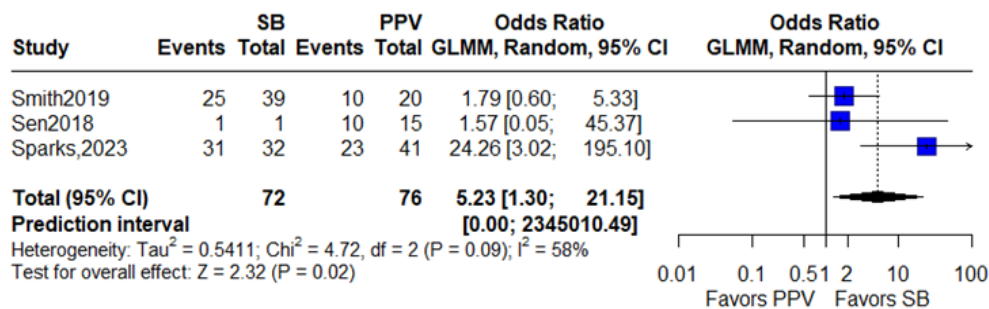


Figure 4: Comparison of Pooled Estimates for Anatomical Success between PPV and SB Groups in Pediatric Retinal Detachment

In total, the three studies comprised 72 patients in the SB only group and 76 patients in the PPV only group. The pooled estimate from the random-effects model yields an odds ratio of 5.23 (95% CI 1.30, 21.15, $P = 0.02$). The heterogeneity among the studies was substantial ($I^2 = 58\%$), suggesting that there is considerable variation in the odds ratios across these studies. The pooled estimate indicates that scleral buckling is associated with more than five times the odds of achieving anatomical success compared to pars plana vitrectomy alone. Sensitivity analysis showed that the results remained statistically significant after omitting two of the studies only.

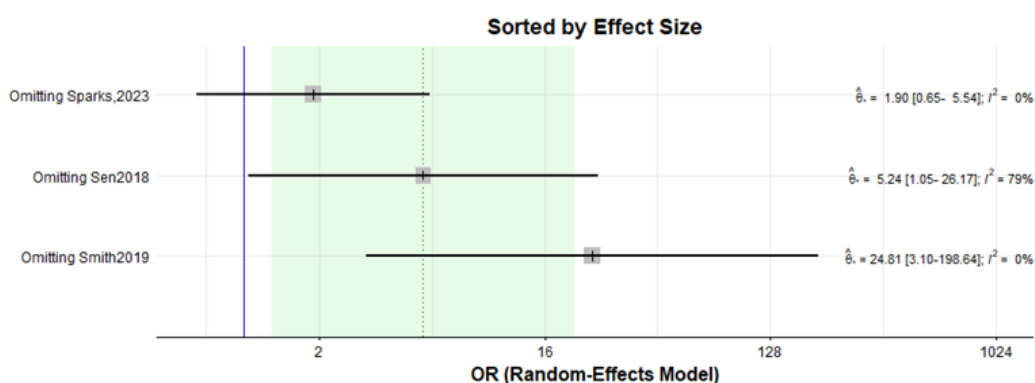


Figure 5: Sensitivity Analysis for the PPV vs SB Comparison

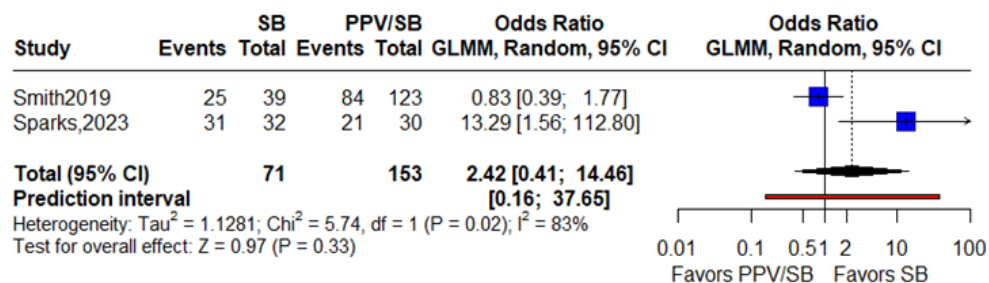


Figure 6: Comparison of Pooled Estimates for Anatomical Success between PPV & SB and SB only Groups in Pediatric Rhegmatogenous Retinal Detachment

Two studies (Only SB surgery compared to combined PPV-SB surgery) were included in the meta-analysis. A total of 71 underwent SB only and 153 patients underwent the combined PPV & SB. The random-effects model's pooled estimate yielded an odds ratio of 2.42 (95% CI 0.41, 14.46, $P = 0.33$). The heterogeneity among the studies was substantial, with an I^2 value of 83%, indicating considerable variation in treatment effects across

studies. The pooled estimate indicates that the combined surgical approach of PPV & SB is not significantly associated with higher odds of achieving anatomical success compared to SB alone.

Table 2

Study	Year	Country	Intervention	Outcomes
Alzaaidi et al. [11]	2013	Saudi Arabia	PPV vs PPV+SB	Anatomical success
Errera et al. [12]	2015	United Kingdom	SB	Anatomical success
Sen et al. [13]	2018	India	PPV	Anatomical success, BCVA
Smith et al. [14]	2019	USA	PPV vs PPV+SB vs SB	Anatomical success
Ghoraba et al. [15]	2020	Egypt	PPV vs PPV+SB	Anatomical success, BCVA
Altaisan et al. [16]	2021	Saudi Arabia	PPV vs PPV+SB	Anatomical success, BCVA
Atik et al. [17]	2022	Turkey	PPV	Anatomical success, BCVA
Sparks et al. [18]	2023	USA	PPV vs PPV+SB vs SB	Anatomical success

Discussion

Pediatric retinal detachments represent 2.9-12.6% of all retinal detachment cases and are a sturdy encounter for vitreo-retinal surgeons [19-21]. Our study included 909 operated pediatric rhegmatogenous retinal detachment eyes, 355 had PPV, 379 had combined PPV & SB and 175 had SB only. We considered anatomical success as being retinal re-attachment from one surgery only without the need to intervene again. Figure 1 shows that the overall anatomical success rates for PPV, combined PPV & SB and SB to be 63%, 66% and 81% respectively.

Further comparison was done combining studies that compared two surgical interventions. Figure 2 shows five studies comparing PPV against combined PPV & SB consisting of 234 PPV eyes and 379 combined PPV & SB eyes. Results were that the odds of anatomical success are not statistically significant between the two groups. On the other hand, Figure 4 shows three studies that directly compared PPV only to SB only and showed that SB had five times the odds of achieving anatomical success. Buckling is believed to have a superior aspect in pediatric eyes due to a relatively healthier RPE pump and a strong firm adherence of the posterior hyaloid to the retinal surface with the presence of a formed vitreous. These factors can also make vitrectomy less effective in alleviating tractions of the vitreo-retinal interface [9,14]. In addition, given the difficulty of inducing a PVD in pediatric eyes and the risk of PVR with incomplete vitrectomy, SB is considered a better surgical option. The selection criteria may play a role as well which, as explained in Sparks et al., is that SB only is considered in milder cases of retinal detachments and vitrectomy is usually done in more advanced cases such as open-globe trauma and advance proliferative vitreoretinopathy [18]. When considering combined PPV & SB to SB only, the conclusion is that the combined approach was not superior to SB only in achieving anatomical success (Figure 6).

In a case series of scleral buckle only, Errera et al. included 104 pediatric eyes that had a primary success rate of 73% and overall success rate of 85% [12]. This series excluded cases with significant PVR, FEVR, previously diagnosed retinal breaks treated with laser and previous vitrectomy for penetrating trauma. In their retrospective study, they noted factors that increased the risk of failure including retinal detachment involving more than 3 quadrants or having more than one retinal break. The degree of myopia, macular status, previous intraocular surgery, and trauma had no influence on the success of SB only. Barth et al. stated that SB only is a preferred option in cases where the break can be pre-operatively localized especially in post-traumatic ora dialysis [22].

Difficulty localizing the break pre-operatively, presence of PVR, penetrating globe injuries and complexity of the retinal detachment may ought to perform a PPV [22,23].

Other modalities of treatment include pneumatic retinopexy. Figueiredo et al. described this in a case series of 20 pediatric patients meeting the PIVOT study criteria [9]. The procedure was done in the office under topical anesthesia and the youngest patient being 9 years of age. The success rate was 75% (15/20). Five cases failed to attach from the first pneumatic, two of them had a second pneumatic, one had PPV, another had PPV & SB and one patient had SB only all of which were successful.

Amblyopia, chronicity, open globe trauma and late presentation are factors that come into play when estimating the visual prognosis of the pediatric patient with retinal detachment. Achieving anatomical success after diagnosis by choosing either SB or combined PPV & SB depending on the severity of the retinal detachment can be an initial step towards a better visual prognosis for the vitreo-retinal surgeon's pediatric patient.

With the implementation of small gauge trans-conjunctival suture-less vitrectomy systems, an inclination of cases of pediatric pars plana vitrectomy has been noticed due to quicker operating time, lessened surgically induced trauma, faster recovery and less patient discomfort [22]. 23-gauge and 25-gauge have been described in the literature, concerns around post-operative hypotony require special attention by using anterior sclerotomies, angled entry of the trochar and cannula, partial fluid air-exchange, careful examination of sclerotomy sites for wound leak and consider sutures in leaking sites [24,25].

Visual outcomes, though clinically crucial, were not consistently analysed due to incomplete or heterogeneous reporting across the included studies. Several studies described visual improvement qualitatively or used differing measurement systems (e.g., Snellen vs. log MAR), making quantitative synthesis unreliable. As a result, this meta-analysis focused primarily on anatomical success. Future research should adopt standardized reporting of visual outcomes with consistent follow-up intervals to better correlate anatomical success with functional vision recovery.

The absence of consistent Proliferative Vitreoretinopathy (PVR) classification across the included studies limited our ability to perform a subgroup analysis based on disease severity. PVR is a well-recognized determinant of surgical success in rhegmatogenous retinal detachment, and its omission from many pediatric series reflects a broader gap in the literature. Variability in case complexity and PVR stage likely contributed to some of the heterogeneity captured by our random-effects model. Future studies should adopt standardized PVR grading systems and report them systematically to allow stratified analyses and more clinically meaningful comparisons [26].

Another important consideration is selection bias across the included studies. Scleral buckle is often performed in milder, localized retinal detachments with identifiable breaks, whereas pars plana vitrectomy or combined PPV + SB are typically reserved for more complex cases involving extensive detachment, proliferative vitreoretinopathy, or trauma. Consequently, the higher single-surgery success rates observed with scleral buckle likely reflect differences in baseline case severity rather than true procedural superiority. This inherent bias underscores the need for prospective comparative studies using standardized case classifications.

Several additional clinical confounders likely influenced the outcomes reported across studies. The aetiology of retinal detachment varied considerably, including traumatic, myopic, and congenital causes, each carrying distinct prognostic implications. Because the current meta-analysis focused specifically on rhegmatogenous retinal detachment (RRD), most included cases were trauma-related, which inherently represent more complex presentations with extensive breaks, vitreous haemorrhage, and a higher risk of proliferative vitreoretinopathy (PVR). This distribution may partially explain the lower single-surgery success rates observed in the vitrectomy subgroups. Macular status at presentation (macula-on versus macula-off) also significantly affects both anatomical and functional recovery yet was not consistently documented across studies. Moreover, amblyopia, a common cofactor in pediatric populations, can limit visual rehabilitation even after anatomical reattachment. The lack of uniform reporting and stratification by these confounders restricts the ability to isolate the true effect of surgical technique on outcomes and likely con-

tributes to the interstudy heterogeneity observed.

Due to the rarity of the condition, there are several limitations noted within the literature and by overcoming such barriers and standardizing reports we anticipate having more reliable results that can have a positive effect on the overall management of pediatric rhegmatogenous retinal detachment patients. In our opinion studies should specify the following: the location of the retinal detachment especially in cases of scleral buckle, location and number of retinal breaks/tears, surgical intervention done, tamponade material selection and its effect on surgical success and the complications of the different surgical interventions. These certainly will aid in developing a more detailed algorithm and approach for cases of pediatric rhegmatogenous retinal detachments.

Limitations of our paper is that it included only studies of rhegmatogenous retinal detachments in pediatric age groups. Thus, these results may not be relevant to other etiologies of pediatric retinal detachments.

Conclusion

Our systematic review and meta-analysis confirm known knowledge that scleral buckle may be preferred in cases of pediatric rhegmatogenous retinal detachments. We conclude that scleral buckle is the most successful of the three interventions. Further details are needed in published literature to have enough to provide a clearer approach in selecting the most suitable surgical intervention in more complex cases that can aid in establishing an evidence-based approach in pediatric rhegmatogenous retinal detachment cases increasing future success rates.

Conflict of Interest

We declare no potential conflict of interest with respect to research, authorship and/or publication of this article.

Acknowledgements and Disclosure:

Funding: No funding or grant support.

Authorship: All authors attest that they meet the current ICMJE criteria for Authorship.

Conflict of Interest: The authors declare that they have no conflict of interest.

Declaration of Generative AI and AI-assisted technologies in the writing process: not used.

Acknowledgements: None.

PROSPERO registration ID CRD42024527399

References

1. Fivgas GD, Capone A Jr (2001) Pediatric rhegmatogenous retinal detachment. *Retina* 21: 101-106.
2. Eibenberger K, Sacu S, Rezar-Dreindl S, Schmidt-Erfurth U, Stifter E, et al. (2021) Clinical characteristics and surgical outcome of pediatric and early adulthood retinal detachment. *Eur J Ophthalmol* 31: 1367-1374.
3. Fong AH, Yip PP, Kwok TY, Tsang CW (2016) A 12-year review on the aetiology and surgical outcomes of paediatric rhegmatogenous retinal detachments in Hong Kong. *Eye (Lond)* 30: 355-361.
4. Nuzzi R, Lavia C, Spinetta R (2017) Paediatric retinal detachment: a review. *Int J Ophthalmol* 10: 1592-1603.
5. Yokoyama T, Kato T, Minamoto A, Sugihara A, Imada M, et al. (2004) Characteristics and surgical outcomes of paediatric retinal detachment. *Eye (Lond)* 18: 889-892.
6. Butler TK, Kiel AW, Orr GM (2001) Anatomical and visual outcome of retinal detachment surgery in children. *Br J Ophthalmol* 85: 1437-1439.
7. Gan NY, Lam WC (2018) Special considerations for pediatric vitreoretinal surgery. *Taiwan J Ophthalmol* 8: 237-242.
8. Yeo DCM, Nagiel A, Yang U, Lee TC, Wong SC (2018) Endoscopy for Pediatric Retinal Disease. *Asia Pac J Ophthalmol (Phila)* 7: 200-207.
9. Figueiredo N, Warder DC, Muni RH, Lee WW, Yong SO, et al. (2022) Pneumatic retinopexy as a treatment for rhegmatogenous retinal detachment in pediatric patients meeting PIVOT criteria. *Can J Ophthalmol* 57: 359-363.
10. Ranchod TM, Capone A Jr (2011) Tips and tricks in pediatric vitreoretinal surgery. *Int Ophthalmol Clin* 51: 173-183.
11. Al-Zaaidi S, Al-Rashaed S, Al-Harathi E, Al-Kahtani E, Abu El-Asrar AM (2013) Rhegmatogenous retinal detachment in children 16 years of age or younger. *Clin Ophthalmol* 7: 1001-1014.
12. Errera MH, Liyanage SE, Moya R, Wong SC, Ezra E (2015) Primary scleral buckling for pediatric rhegmatogenous retinal detachment. *Retina* 35: 1441-1449.

13. Sen P, Shaikh SI, Sreelakshmi K (2018) Rhegmatogenous retinal detachment in paediatric patients after pars plana vitrectomy and sutured scleral-fixated intraocular lenses. *Eye (Lond)* 32: 345-351.
14. Smith JM, Ward LT, Townsend JH, Yan J, Hendrick AM, et al. (2019) Rhegmatogenous Retinal Detachment in Children: Clinical Factors Predictive of Successful Surgical Repair. *Ophthalmology* 126: 1263-1270.
15. Ghoraba HH, Mansour HO, Abdelhafez MA, El Gouhary SM, Zaky AG, et al. (2020) Comparison Between Pars Plana Vitrectomy with and without Encircling Band in the Treatment of Pediatric Traumatic Rhegmatogenous Retinal Detachment. *Clin Ophthalmol* 14: 3271-3277.
16. Al Taisan AA, Alshamrani AA, AlZahrani AT, Al-Abdullah AA (2021) Pars Plana Vitrectomy vs Combined Pars Plana Vitrectomy-Scleral Buckle for Primary Repair of Pediatrics Retinal Detachment. *Clin Ophthalmol* 15: 1949-1955.
17. Kemer Atik B, Erdogan G, Kirmaci Kabakci A, Artunay O (2022) The outcomes of primary pars plana vitrectomy alone as a first surgical procedure in pediatric rhegmatogenous retinal detachment. *Int Ophthalmol* 42: 3469-3478.
18. Sparks ME, Davila PJ, He YG, Wang AL (2023) Pediatric Rhegmatogenous Retinal Detachments: Etiologies, Clinical Course, and Surgical Outcomes. *J Vitreoretin Dis* 7: 139-143.
19. Butler TK, Kiel AW, Orr GM (2001) Anatomical and visual outcome of retinal detachment surgery in children. *Br J Ophthalmol* 85: 1437-1439.
20. Chang PY, Yang CM, Yang CH, Huang JS, Ho TC, et al. (2005) Clinical characteristics and surgical outcomes of pediatric rhegmatogenous retinal detachment in Taiwan. *Am J Ophthalmol* 139: 1067-1072.
21. Al Abdulsalm O, Al Habboubi H, Mura M, Al-Abdullah A (2022) Re-Vitrectomy versus Combined Re-Vitrectomy with Scleral Buckling for Pediatric Recurrent Retinal Detachment. *Clin Ophthalmol* 16: 877-884.
22. Barth T, Zeman F, Helbig H, Oberacher-Velten I (2017) Clinical Features and Outcome of Paediatric Retinal Detachment. *Ophthalmologica* 237: 63-72.
23. Soheilian M, Ramezani A, Malihi M, Yaseri M, Ahmadi H, et al. (2009) Clinical features and surgical outcomes of pediatric rhegmatogenous retinal detachment. *Retina* 29: 545-551.
24. Singh R, Kumari N, Katoch D, Sanghi G, Gupta A, et al. (2014) Outcome of 23-gauge pars plana vitrectomy for pediatric vitreoretinal conditions. *J Pediatr Ophthalmol Strabismus* 51: 27-31.
25. Gonzales CR, Singh S, Schwartz SD (2009) 25-Gauge vitrectomy for paediatric vitreoretinal conditions. *Br J Ophthalmol* 93: 787-790.
26. Haddaway NR, Page MJ, Pritchard CC, McGuinness LA (2022) PRISMA2020: An R package and Shiny app for producing PRISMA 2020-compliant flow diagrams, with interactivity for optimised digital transparency and Open Synthesis. *Campbell Systematic Reviews* 18: e1230.